

A Comparative Study of Pre-operative and Post-operative Approaches to Ultrasound Guided Transversus Abdominis Plane Block for Post-operative Analgesia in Patients Undergoing Total Abdominal Hysterectomy

Raja Shekar Reddy M¹, Rajeev BM², Prasanna GS³

¹Assistant professor, Department of Anesthesia, Dr. VRK Women's Medical College, Aziz Nagar, Hyderabad, Telangana 500075, India. ^{2,3}Consultant, Department of Anesthesia, Adarsha Health Care, PJ Extension, Davangere, Karnataka 577002, India.

Abstract

Background: Effective post-operative analgesia is obtained by Transversus Abdominis Plane Block and it decreases consumption of post-operative opioids significantly after abdominal surgeries. **Aims:** To evaluate which period is more effective for Transversus Abdominis Plane (TAP) Block administration using Ultrasound guidance for post-operative analgesia in patients undergoing total abdominal hysterectomy. **Materials and Methods:** This was a prospective randomized, double blind study conducted on 70 patients between ages of 19 and 66 years, with ASA class I-II. The subjects were divided into two Groups. The TAP block was given pre-operatively to Group I patients and was given post-operatively to the Group II patients. These patients were scheduled to undergo open total abdominal hysterectomy. Both the groups received standard general anesthetic technique. In the post-operative period tramadol (20 mg/2 ml bolus intravenous and then 10 mg/ml I.V. with a five minute lock out period) was given that was controlled by the patient. Metoclopramide 10 mg I.V. 8 hourly was given as per PONV score. The Numerical Rating Scale was used to assess pain. The NRS scores were recorded at 2, 4, 6, 12 and 24 hours post-operatively. The NRS at rest, the NRS on movement and sedation score were recorded. Tramadol consumption in both groups was compared. **Results:** When both the groups were compared it was observed that the NRS scores at rest were significantly lower in Group 2 at 2 and 4 hours post-operatively ($p < 0.05$). In Group 2, the 24 hour tramadol consumption was significantly lower than that of Group 1 ($p < 0.05$). **Conclusion:** Post-operative ultrasound guided TAP Block confers significantly reduced pain scores in the early post-operative periods of TAH cases as compared to pre-operative TAP block.

Keywords: Transversus Abdominis Plane (TAP) Block; Numerical rating scale NRS; Tramadol in PCA in TAH.

How to cite this article:

Raja Shekar Reddy M, Rajeev BM, Prasanna GS. A Comparative Study of Pre-operative and Post-operative Approaches to Ultrasound Guided Transversus Abdominis Plane Block for Post-operative Analgesia in Patients Undergoing Total Abdominal Hysterectomy. Indian J Anesth Analg. 2019;6(6 Part -I):1990-1994.

Introduction

Total Abdominal Hysterectomy (TAH) is a common and major surgical procedure performed which results in substantial pain and discomfort in

the post-operative period.¹ These patients require a multimodal post-operative pain management regimen that provides high quality analgesia with minimal side effects. A substantial component of the pain experienced by patients after abdominal

Corresponding Author: Rajeev BM, Consultant, Department of Anesthesia, Adarsha Health Care, PJ Extension, Davangere, Karnataka 577002, India

E-mail: drrajmuddalli@gmail.com

Received on 15.07.2019, **Accepted on** 26.08.2019

surgery is from the abdominal wall incision.² A promising approach for the provision of post-operative analgesia after abdominal incision is to block the sensory nerve supply to the anterior abdominal wall.³ However, the clinical utility of current approaches to the blockade of these nerve afferents, such as abdominal field blocks is limited, and the degree of block achieved can be unpredictable.

To reduce the consumption of opioids and support the management of post-operative pain, ultrasound guidance provides better localization and successful block procedures.¹ The use of Ultrasound guidance for TAP block is growing. TAP Block was reported as a safe and successful adjunct to outcomes in multi modal analgesia after various abdominal surgeries.² Type of surgery, volume of local anesthetic solution and injection timing are important considerations for TAP block administration. This procedure can be performed both pre operatively and post operatively. In some publications, the pre-operative period is recommended as the optimal time for TAP Block administration rather than the post-operative period.³ The aim of this study was to evaluate as to which period is more effective for TAP Block administration using US guidance for post-operative analgesia in patients undergoing total abdominal hysterectomy.

Materials and Methods

This was a prospective randomized, double blinded study which was conducted on 70 patients between ages of 19 and 66 years with ASA Classes I-II. These patients were scheduled to undergo open total abdominal hysterectomy. This study was conducted through February 2019 to June 2019. Written informed consent was taken from all patients and this study was approved by Institutional ethical committee. Patients were excluded if they showed a history of allergy to the drugs used, had coagulation pathology, opioid tolerance, diabetes mellitus or hypertension. By using computer generated randomization, patients were divided into two groups.

- Group I consisted of patients who received an US guided TAP Block prior to surgical procedure followed by standard general anesthesia;
- Group II consisted of patients who underwent US guided TAP Block procedure after surgery.

Post-operatively, Numerical Rating Scale (NRS) scores were recorded and multi modal analgesia regime was in place for post-operative analgesia. This analgesia was patient-controlled. The TAP block establishment was blinded to both patients and post-operative raters. The study group assignments were concealed until data were collected. Pre-medication was not administered to any patient. Standard Monitoring included electrocardiography (ECG), peripheral oxygen saturation (SpO₂), Non-invasive Blood Pressure (NIBP), End tidal Carbon di oxide (EtCO₂) and heart rate monitoring. General anesthesia was given to all patients. Patients were induced with remifentanyl (1 µg/kg), propofol (2 mg/kg), vecuronium (0.1 mg/kg). At a concentration of 7-8% Desflurane in a mixture of 60% N₂O and 40% O₂, maintenance of anesthesia was continued. The same experienced anesthetist performed all the TAP blocks. The TAP Block was performed using 6-13 MHz linear probe with real time US guidance with a 22 G 80 mm needle, using In-plane technique. Ultra sound probe was placed transversely in the flank between the anterior superior iliac spine and the coastal margin. The external oblique, the internal oblique and transversus abdominis muscles were identified. The needle placement was done between the internal oblique muscle and transversus abdominis muscle. Negative aspiration was conducted before injecting local anesthetic. Then 1.5 mg/kg of 0.2% ropivacaine (maximum dose of 150 mg on each side) was injected. The same procedure was repeated on the other side. In the Post-anesthetic care unit (PACU) patients were observed for at least 30 minutes and were transferred to the post-surgical ward, where their vital signs were monitored and maintained.

For analgesia, multi modal analgesia was employed including Paracetamol, NSAIDs and Patient Controlled Analgesia with Tramadol (PCA set) was used. The PCA contained tramadol at a concentration of 20 mg/2 ml or 10 mg/ml. The patients were already instructed on the correct way to use the PCA and used it for NRS more than 4. Patients of both the groups received PCA Tramadol analgesia as bolus of 2 ml and then 10 mg/ml with a 5 minutes lockout time. The upper safe limit of tramadol was kept as 500 mg in 24 hours. For patients complaining of post-operative nausea and/or vomiting, Metoclopramide 10 mg I.V. was used when the PONV score was 2 or more than 2. The analgesic use was recorded. The NRS at rest, NRS on movement and the sedation scores at 2, 4, 6, 12 and 24 hours post-operatively were recorded. The NRS score of 0 = no pain, 1, 2, 3, 4, 5, 6, 7, 8, 9 and 10 = worst pain ever experienced. Nausea

was measured using a 4-point scoring system, *i.e.*, no nausea = 0, mild nausea = 1, moderate nausea = 2, severe nausea = 3. A 4-point sedation scale was used to measure sedation (0 = awake, 1 = prone to sleeping, 2 = asleep, and 3 = deep sleep).

Using SPSS 16.0, statistical analysis was performed. Data were expressed as the mean \pm SD. Statistically, $p < 0.05$ was considered to be significant, $p < 0.01$ was considered to be highly significant.

Results

In this study, a total of 70 patients were included.

Table 1: Demographic characteristics and duration of surgery

Characteristics	Group I (n = 35)	Group II (n = 35)
Weight (Kg)	76.9 \pm 12.4	73 \pm 11.3
Age (years)	49.1 \pm 6.9	51.4 \pm 4.7
Height (cm)	159 \pm 5.1	162 \pm 6.4
Duration of surgery (min)	174 \pm 51.7	170 \pm 57.1

Table 1 shows that the weight in group I was 76.9 \pm 2.4 kg and in group II it was 73 \pm 11.3 kg. The age in Group I was 49.1 \pm 6.9 years and in Group II it was 51.4 \pm 4.7 years, the height was 159 \pm 5.1 cm in Group I and in Group II, it was 162 \pm 6.4 cm, duration of surgery was 174 \pm 51.7 minutes in Group I and it was 170 \pm 57.1 minutes in Group II. In demographic characteristics and duration of surgery, the patients were similar.

Table 2: Post-operative Numerical Rating Scale (NRS) pain scores at rest in each group

	Group I (n = 35)	Group II (n = 35)	p-Value
Immediate post-operative period	5.6	5.8	> 0.05
1 hr	5.2	5	> 0.05
2 hrs	5	4	< 0.01
4 hrs	4	3	< 0.01
6 hrs	2.8	2.7	> 0.05
12 hrs	1.8	1.8	> 0.05
24 hrs	0.8	0.8	> 0.05

Table 2 shows that NRS pain scores at rest were significantly lower in Group 2 at 2 and 4 hours ($p < 0.05$), when Group 1 was compared with Group 2, displays **Fig. 1**.

Table 3: Post-operative Numerical Rating Scale (NRS) pain scores on movement in each group

	Group I (n = 35)	Group II (n = 35)	p-Value
Immediate post-operative period	6.6	6.4	> 0.05
1 hr	7	6.8	> 0.05
2 hrs	6	6	> 0.05
4 hrs	5	5	> 0.05
6 hrs	4	4	> 0.05
12 hrs	2	2	> 0.05
24 hrs	1.2	1.2	> 0.05

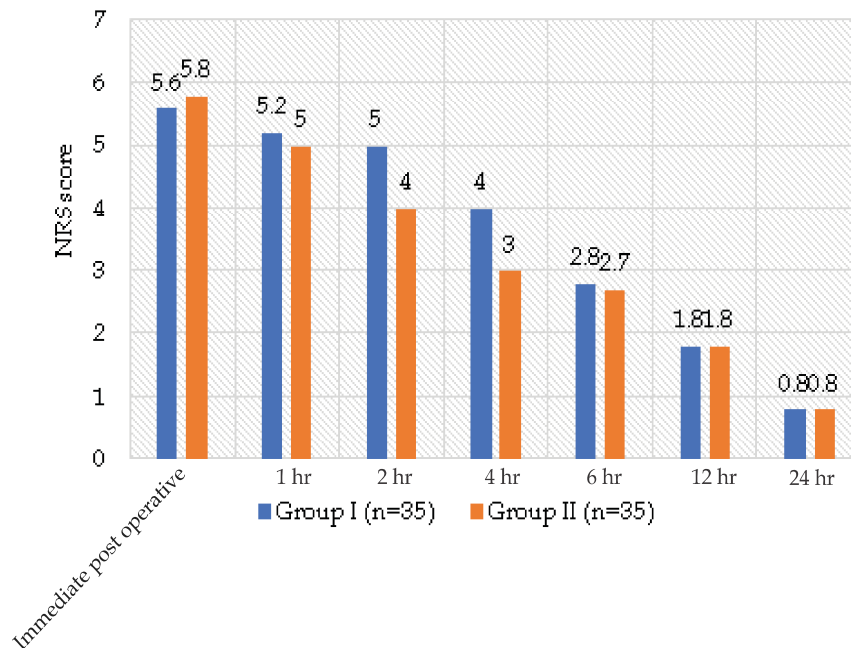


Fig. 1: NRS score in both groups post-operatively at rest

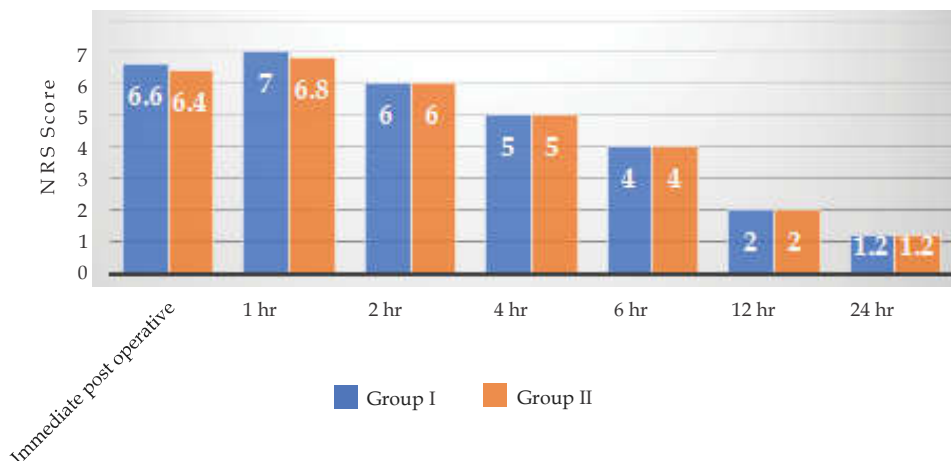


Fig. 2: NRS score in both groups post-operatively on movement

Table 3 shown that in the both groups, NRS pain scores on movement were similar in all monitoring periods ($p > 0.05$). Sedation scores were similar in both groups and no excessive sedation was observed ($p > 0.05$).

Consumption of Tramadol

For the pre-operative TAP Group (Group I) the mean Tramadol consumption was 286 mg with a standard deviation of 86, and for the post-operative TAP Group (Group II) the mean was 216 mg with standard deviation of 72. This was statistically significant $p < 0.05$ as shown in table 4. There was not much difference in the consumption of anti-emetic/metoclopramide for both the groups.

Table 4: Comparison of consumption of Tramadol in both the groups

	Group I	Group II	p-Value
Range	458-114 mg	360-72 mg	< 0.05
Mean of total drug consumption	286 mg	216	< 0.05
Standard Deviation	+/-86	+/-72	< 0.05

Discussion

In total abdominal hysterectomy patients, compared to pre-operative administration of block, it was found in this present study that post-operative administration of the US guided TAP Block significantly reduced the 24 hours consumption of tramadol and at 2 and 4 hours along with decreased pain scores. In a wide variety of abdominal surgeries, the TAP Block has been preferred for post-operative analgesia. Peng K *et al.*⁴ reported that after TAP Block, post-operative NRS pain score at rest and on movement were reduced. The

same results were also observed in Baeriswyl⁵ and Gasanova I⁶ studies. In studies performed by O'Donnell BD,⁷ Carney J,⁸ McDonnell JG,⁹ Niraj G,¹⁰ NRS pain scores between 1 and 4, on a scale of 0-10, were observed. Whereas in the present study, NRS pain scores were recorded at all interval periods, at rest and on movement in both the groups. Mrunalini P¹¹ reported that anatomical landmark technique, blind technique or US guided technique can be the techniques for TAP Block. The technique using palpation alone is a blind technique which is also known as pop technique, is associated with serious complications which was reported in Shanmugam T,¹² Johr M¹³ and Forooq M¹⁴ *et al.* studies. The movement of the needle can be facilitated by US guidance and it also helps to control distribution of local anesthetics to appropriate regions. The quality of the nerve Block is improved by Ultrasound as reported by Petersen PL.³ The procedure time and the number of attempts is reduced, block start time is accelerated and prevents gastrointestinal organ injury if done by ultrasound guidance. The present study is more advantageous as we performed using ultrasound guidance without any complication. A study done by Amr YM *et al.*¹⁵ reported that ideal period for TAP Block is the pre-operative period and it was superior in reducing the severity of acute pain, usage of analgesia, side effects and pain incidence compared to post-operative period TAP Block. Acute post-operative analgesic efficacy can be affected by timing of injection. Abdallah FW *et al.*² found that out of 18 studies, TAP pre-operative block was done in half of the studies, and other performed post-operatively. Optimal timing for TAP Block was in the pre-operative period as reported by Olivera *et al.*¹⁶ In our study, in contrast to the above results, post-operative TAP Blocks were more beneficial in the early period of pain at rest. Post-operative consumption of morphine was

reduced in the study by Abdallah FW *et al.*² and Olivera *et al.*¹⁶ studies.

Conclusion

In the present study, the post-operative ultrasound guided TAP Block administration, in the early period, reduced the pain scores significantly. It also reduced the 24 hours consumption of tramadol when compared to pre-operative administration of the block in total abdominal hysterectomy patients.

References

1. Bhatia N, Jyotsna Wig SA, Kaur G. Comparison of posterior and subcostal approaches to ultrasound-guided transverse abdominis plane block for post-operative analgesia in laparoscopic cholecystectomy. *J Clin Anesth.* 2014;26:294-299.
2. Abdallah FW, Chan VW, Brull R. Transversus abdominis plane block: A systematic review. *Reg Anesth Pain Med.* 2012;37:193-209.
3. Petersen PL, Mathiesen O, Torup H, *et al.* The transversus abdominis plane block: A valuable option for post-operative analgesia; A topical review. *Acta Anesthesiol Scand.* 2010;54:529-535.
4. Peng K, Ji FH, Liu HY, *et al.* Ultrasound-guided Transversus Abdominis Plane Block for Analgesia in Laparoscopic Cholecystectomy: A Systematic Review and Meta-analysis. *Med Princ Pract.* 2016;25:237-246.
5. Baeriswyl M, Kirkham KR, Kern C, *et al.* The Analgesic Efficacy of Ultrasound-Guided Transversus Abdominis Plane Block in Adult Patients: A Meta-Analysis. *Anesth Analg.* 2015;121:1640-1654.
6. Gasanova I, Alexander J, Ogunnaike B, *et al.* Transversus Abdominis Plane Bloc versus Surgical Site Infiltration for Pain Management after open total abdominal hysterectomy. *Anesth Analg.* 2015;121:1383-1388.
7. O'Donnell BD, McDonnell JG, McShane AJ. The Transversus Abdominis Plane (TAP) Block in open retropubic prostatectomy. *Reg Anesth Pain Med.* 2006;31:91.
8. Carney J, McDonnell JG, Ochana A, *et al.* The transversus abdominis plane block provides effective post-operative analgesia in patients undergoing total abdominal hysterectomy. *Anesth Analg.* 2008;107:2056-2060.
9. McDonnell JG, Curley G, Carney J, *et al.* The analgesic efficacy of transversus abdominis plane block after cesarean delivery: A randomized controlled trial. *Anesth Analg.* 2008;106:186-191.
10. Niraj G, Searle A, Mathews M, *et al.* Analgesic efficacy of ultrasound-guided transversus abdominis plane block in patients undergoing open appendectomy. *Br J Anesth.* 2009;103:601-605.
11. Mrunalini P, Raju NVR, Nath VN, *et al.* Efficacy of transversus abdominis plane block in patients undergoing emergency laparotomies. *Anesth Essays Res.* 2014 Sep-Dec;8(3):377-82. doi:10.4103/0259-1162.143153..
12. Shanmugam T, Kundra P, Sudhakar S. Iliac compartment block following ilioinguinal iliohypogastric nerve block. *Pediatr Anesth* 2006;16:1084-1086.
13. Jöhr M, Sossai R. Colonic puncture during ilioinguinal nerve block in a child. *Anesth Analg.* 1999;88:1051-1052.
14. Farooq M, Carey M. A case of liver trauma with a blunt regional anesthesia needle while performing transversus abdominis plane block. *Reg Anesth Pain Med.* 2008;33:274-275.
15. Amr YM, Amin SM. Comparative study between effect of pre-versus post-incisional transversus abdominis plane block on acute and chronic post-abdominal hysterectomy pain. *Anesth Essays Res.* 2011;5:77-82.
16. De Oliveira GS Jr, Castro-Alves LJ, Nader A, *et al.* ransversus abdominis plane block to ameliorate post-operative pain outcomes after laparoscopic surgery: A meta-analysis of randomized controlled trials. *Anesth Analg.* 2014;118:454-463.